



## Occlusal Contact Is an Essential Element for Immediate Loading

Philip L Millstein\*, Carlos E. Sabrosa and Karen Geber

\**Department of Restorative Dentistry, Harvard School of Dental Medicine, Boston, Massachusetts, USA*

*Department of Graduate Prosthodontics (Interim), Boston University School of Dental Medicine. Boston, Massachusetts, USA*

*Private practice, Rio de Janeiro, Brazil.*

**Corresponding author:** Philip L Millstein, Department of Restorative Dentistry, Harvard School of Dental Medicine, Boston, Massachusetts, USA, E-mail: pmillsteindmd@gmail.com

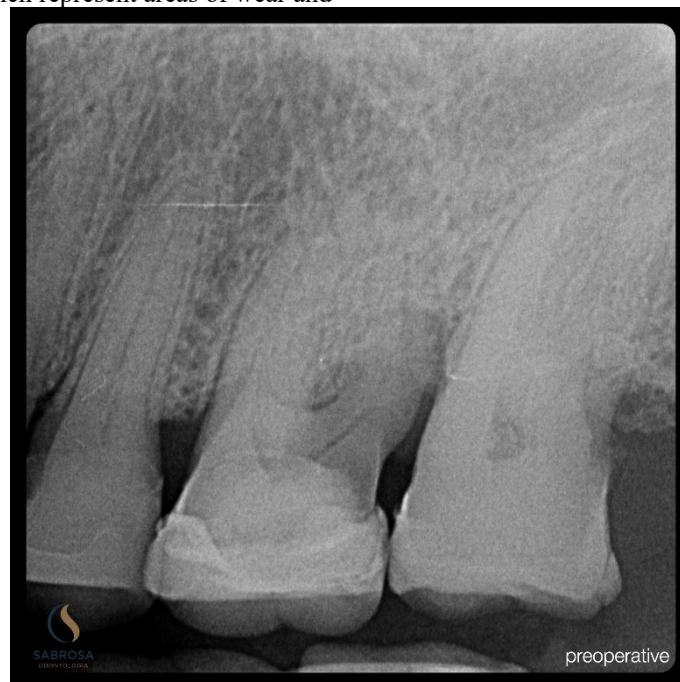### Abstract

Immediate loading is a viable means for implant placement and healing. Careful planning along with occlusal contact placement is suggested.

**Keywords:** Implant, Immediate loading, Occlusal contact, 5 years, Success.

Occlusion is about teeth (1). A good occlusion is good; a bad occlusion is bad. How does a clinician assess occlusion? We look at a frontal facial or side view and judge good from bad according to our aesthetic sense. Other than skeletal malformations there are few ways to make judgement. A definition of occlusion relates to a closed jaw position. Occlusal function refers to many occlusal contact areas working together (2). Each occlusal contact area functions independently. Together they work in unison. The modern day definition of occlusion should be of occlusal contacts because they make an occlusion work. No contact, no function. An occlusal contact forms when two opposing surfaces make contact. Touch is important (3). Contact and touch vary. Size, area, intensity and misplaced areas of contact affect a functioning occlusion (4). We can measure and record contact areas which represent areas of wear and

tear (5). They establish a pattern over time. Each active contact surface differs as does each area in function. No two people have the same occlusal contact profile (6). Occlusion is a general term whereas occlusal contact is specific. Touch and intensity of contact are reduced in endodontically treated teeth (7). Implants are rigid and not touch sensitive (8). Vital teeth have mechanoreceptors in the periodontal housing to guide their micro movements (9). They also have a vital blood supply (10). Occlusal contact is a dynamic process which includes increased blood flow. Teeth vibrate with micro movements as contact intensity increases. The dynamic of contact is unknown. Wear is a vital process. Immediate implant loading can be successful when there is occlusal contact. **Figures. 1,2,3.** Patients with knee or hip replacements walk immediately after surgery (11).



**Figure 1.** Radiograph of failed maxillary first molar.

Received: April 24, 2026; Revised: April 27, 2026; Accepted: April 28, 2026

Citation: Millstein PL, Sabrosa CE & Geber K. (2026) Occlusal Contact Is an Essential Element for Immediate Loading. J Oral Health Dent Res, 5(3): 1-5.

Copyright: ©2026 Millstein PL, Sabrosa CE & Geber K. This is an open-access article distributed under the terms of the Creative Commons Attribution License, which permits unrestricted use, distribution, and reproduction in any medium, provided the original author and source are credited.

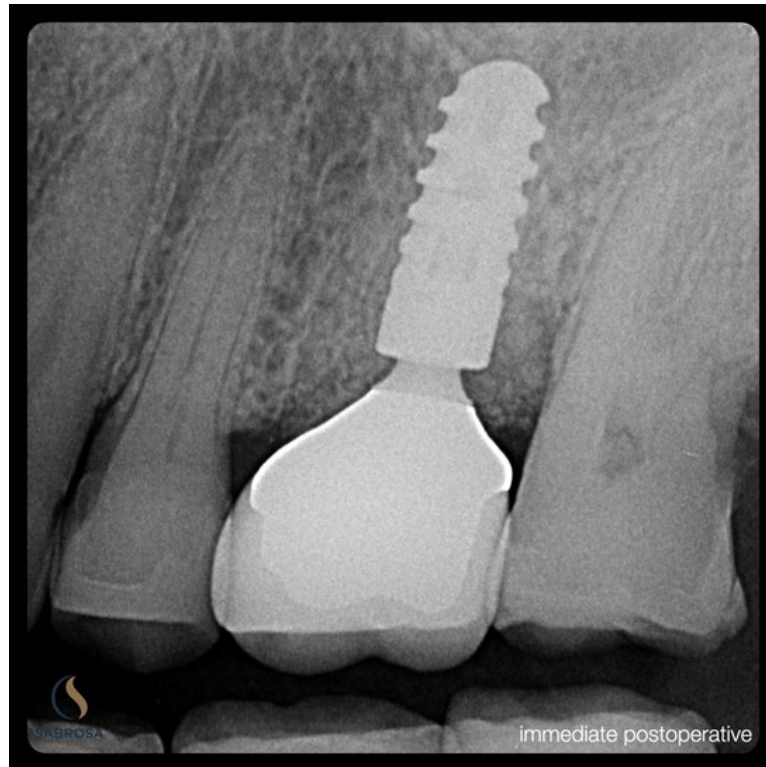


Figure 2. Non traumatic tooth removal is followed by pre planned guided implant placement. Crown is cemented.

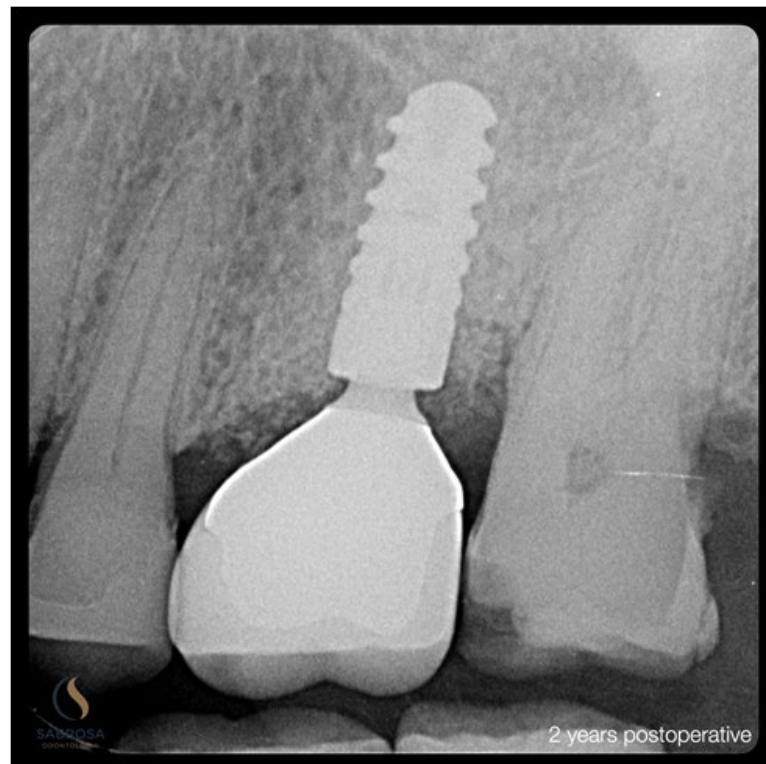
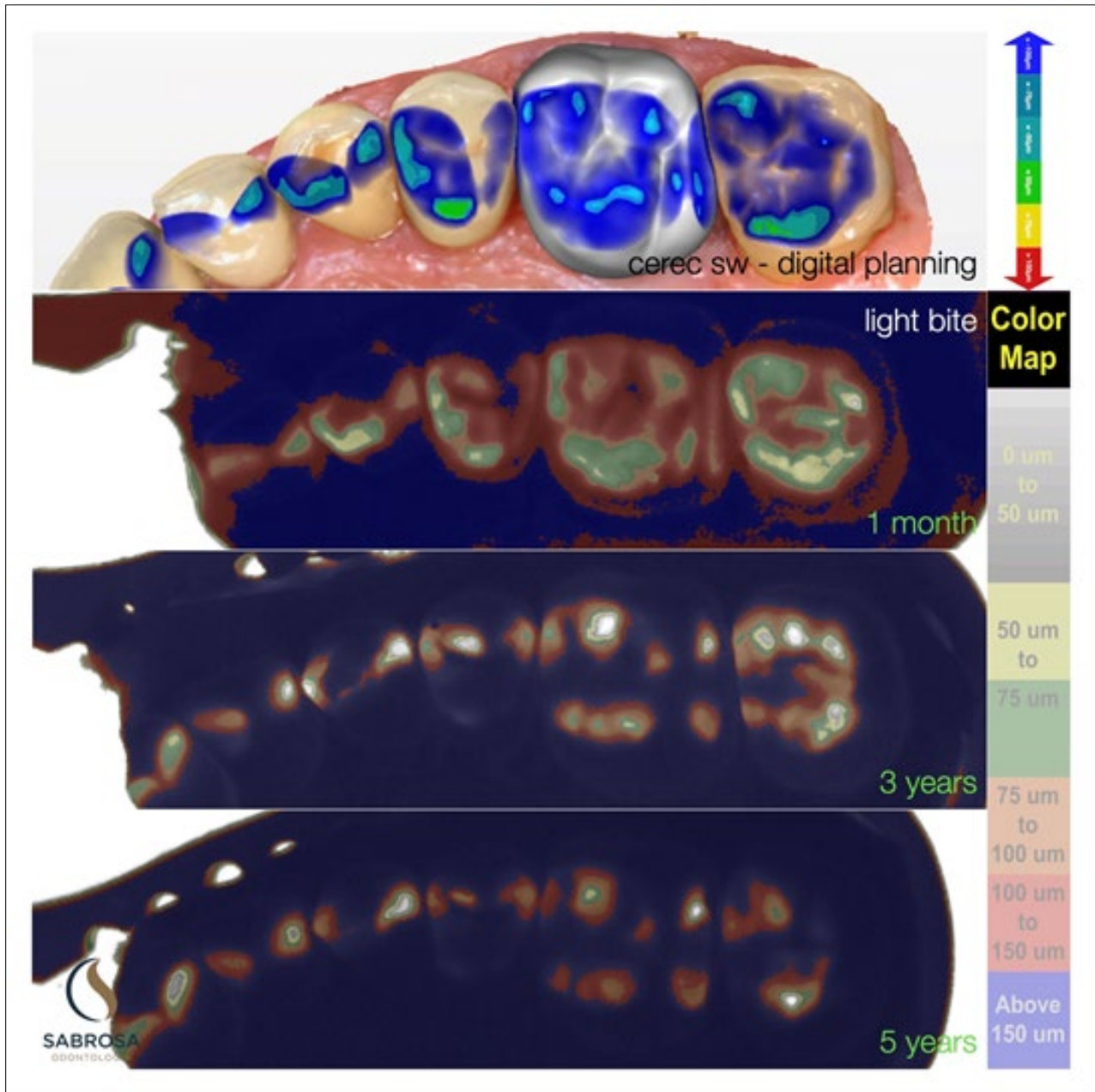


Figure 3. Healing after two years is evident with the distal bone loss being repaired and the ceramic crown in function.

Immediate loading is part of a clinical treatment however success in dentistry often depends on occlusal adjustment at the time of delivery and at subsequent visits. Function is an

important part of healing. The shifting of contact areas and their locations over the years demonstrates the viability of a dynamic process **Figures.4,5.**

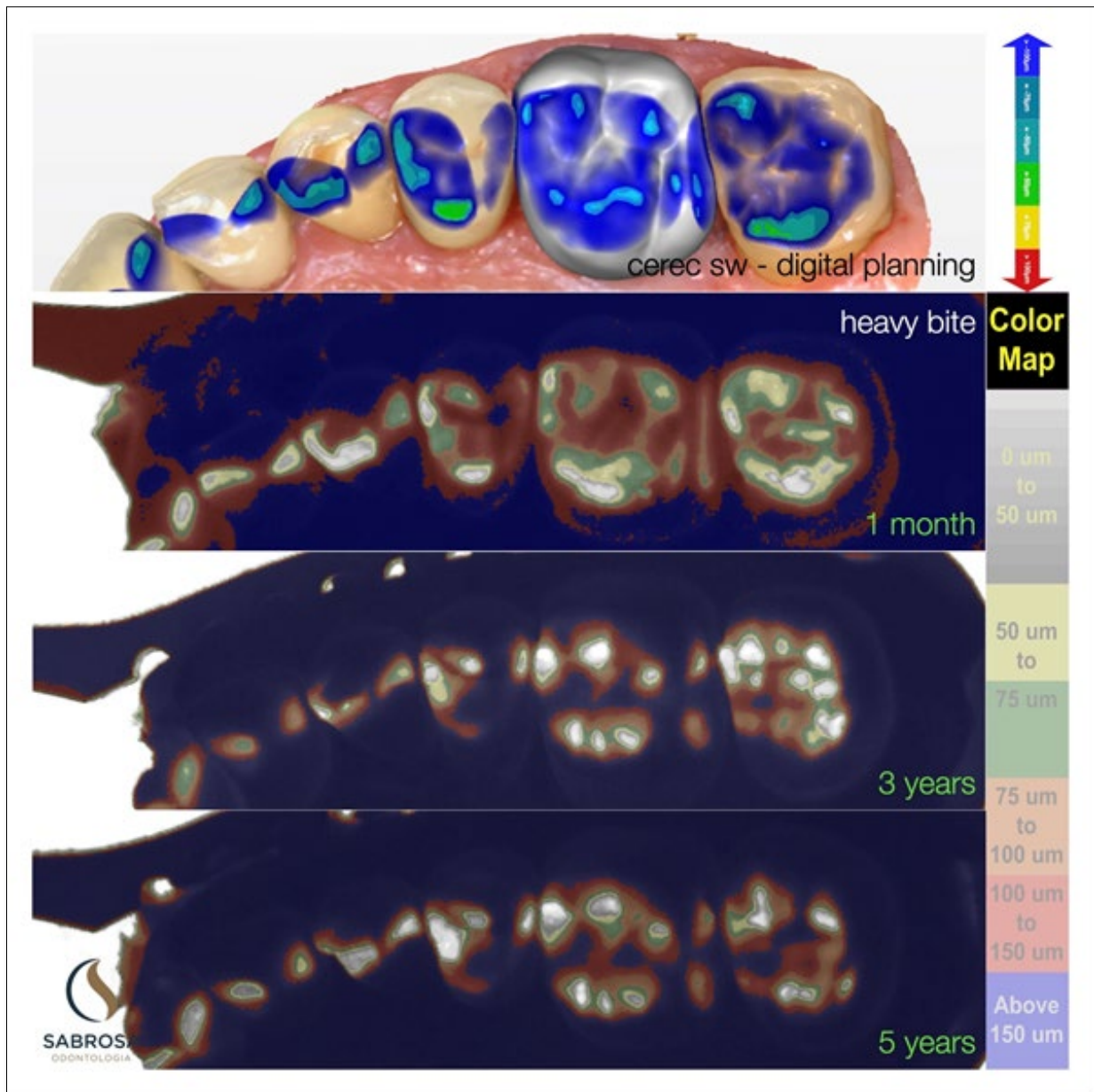


**Figure 4.** Regular closure demonstrates a functioning occlusion. Note the positional occlusal contact changes that occur with time. The immediately loaded implant has been incorporated into the working occlusion.

Occlusal contact is not static. If there was no surface wear static contact would impede function. Wear and movement are normal processes. The TMJ and mandibular positions adjust with occlusal contact change. Implant crown contact areas must be routinely evaluated because they do not adapt to a dynamic occlusion. If there are no permanent occlusal contact records then contact positions can not be reviewed and compared over time. Permanent occlusal contact records remain non existent.

In order to make permanent occlusal contact records the hygienist takes a closed inter occlusal record in a triple tray

using silicone impression material. The tray is placed on an illuminated light surface in a scanner. A camera above is used to photograph the illuminated impression. A permanent record is made and the density of the resultant black and white image is examined using an image analysis program (Image J). Color is applied for easy viewing. Scanning of the photographs may also provide an overview of the dental occlusion in function. Skilled interpretation is an essential element in maintaining occlusal contact stability.



**Figure 5.** Hard closure demonstrates occlusal contact areas which shift in position and intensity over time. The immediately loaded implant was placed five years ago. The occlusion is stable. Wear is a vital process.

**REFERENCES**

1. Google search: Dental occlusion
2. Google search: Oclusal contact
3. Google search: Touch sensitivity
4. Occlusal contact intensity. pubmed.ncbi.nlm.nih.gov
5. Millstein PL, Sabrosa CE, Yung Wai. Occlusal Damage and Bruxism: Early Intervention is Needed. JODHR, 2025; 2583-522X
6. Millstein PL, Merrill EW. Occlusal Contact Recordings in Static and Functional Occlusion: Description of an Observational Method. Journal of Dentistry and Oral Implants; Volume 2, Issue 4. Pg.10-13, 2022.
7. Personal communication: Department of Endodontics, Tufts University School of Dental Medicine. Boston, MA . USA.
8. Personal communication: Department of Restorative Dentistry, Division of Graduate Prosthodontics. Harvard School of Dental Medicine. Boston, MA. USA.
9. Personal communication: Professor M. Perlitch (Ret). Department of Periodontology, Division of Occlusion .Tufts University School of Dental Medicine. Boston, MA. USA.

10. Laura Sanders: From the Heart. Science News. May 4 and 18, 2024.
11. Personal communication: Department of Orthopedics, New England Baptist Hospital. Boston, MA. USA.