

## **Effect of nanoparticles of tranexamic acid on Intra-Abdominal Adhesion after Laparotomy on rat**

### **Abstract**

Intra-abdominal adhesions are a common complication of abdominal surgeries that occur after almost any surgery in this area (especially laparotomy) and can make subsequent abdominal surgeries difficult. These adhesions are actually internal scars that occur following damage to the organs of the abdomen and / or peritoneum. In this study, the effect of nano - drug tranexamic acid on intra-abdominal adhesions in rats, microscopically and macroscopically, was investigated. 30 adult male Wistar rats, with an average weight of 350-300 gr, were randomly divided into 3 equal treatment groups. For laparotomy, rats were anesthetized by intramuscular injection of ketamine 10 % (50 mg / kg) and xylazine 2 % (5 mg / kg). Then adhesion was induced in all rats by scratching the abdominal wall. There were three treatment groups, including the group treated with the nano drug Tranexamic acid ( 50 mg/kg ), the group treated with the drug Tranexamic acid ( 50 mg/kg ), and the control group. On the 14th and 28th day, all the rats were subjected to laparotomy again and the degree of intra-abdominal adhesions created in them was evaluated macroscopically and microscopically. The macroscopic examination of the adhesions has shown that the formation of adhesion bands in the treatment groups with nano - drug and drug ( tranexamic acid ) was significantly lower than the control group (  $P < 0/05$  ). In such a way that the lowest amount of adhesion was observed in the treatment group with the nano drug and the highest amount of adhesion was observed in the control group. Microscopic examination of slides prepared from adhesion lesions also showed that the amount of inflammation and formation of fibrotic tissue in the treatment groups with nano drug and drug ( tranexamic acid ) was significantly lower than the control group (  $P < 0/05$  ). In such a way that the lowest amount of inflammation and the formation of fibrotic tissue was related to the treatment group with nano drug and the highest amount was related to the control group.

### **Introduction**

Intra-abdominal adhesions are one of the most common complications of abdominal surgery, which affects more than 90% of patients undergoing abdominal surgery and can even lead to death ( 1 ). These adhesions are actually fibrous joints that connect the abdominal organs to each other or attach them to the abdominal wall. In most cases, these adhesions remain asymptomatic, although they are sometimes accompanied by symptoms, in which case they are called adhesive disease. Because these adhesions cannot be detected by routine laboratory and imaging techniques, patients with the lesion will suffer from long-term complications such as intermittent obstruction of the small intestine ( 2 ). The most important etiological causes of these adhesions are abdominal surgery (in which laparotomy is most important), infection and inflammation in this area, and radiation therapy in the abdominal area ( 2 ). Although the pathophysiology of adhesions is not yet fully understood, these lesions are thought to occur in three stages: destruction and rupture of

mesothelial surfaces, the process of fibrino coagulation, and inflammation . Although abdominal adhesions have no specific symptoms, symptoms such as chronic bloating, abdominal cramps, constipation or increased bowel movements, nausea, signs of intestinal obstruction, and bleeding from the rectum may be associated with this complication ( 2 ) . To prevent intra-abdominal adhesions , there are three main strategies: minimizing the damage to the peritoneum , drug intervention (use of drugs that balance the production and breakdown of fibrin) and also the use of mechanical barriers that prevent the connection and adhesion of intra-abdominal organs to each other ( 3 , 7 ) . Common complications of intra - abdominal adhesions include bowel obstruction, infertility (in females), and chronic pelvic pain ( 4 , 5 , 6 ) .

Tranexamic acid is a compound with a chemical structure similar to the amino acid lysine, which competitively prevents the conversion of plasminogen to plasmin and actually prevents its activation. This compound, as mentioned, prevents the breakdown of fibrin clots (by plasmin) and therefore has anti-fibrinolytic properties. The most important use of this drug is to prevent bleeding in cases of severe bleeding and thus reduce the need for blood transfusions . It also reduces inflammatory responses by inhibiting plasminogen ( 8 , 9 , 10 ) . Tranexamic acid is used intravenously, orally and topically in various cases such as hemorrhagic shock, heart surgery, eye bleeding (Traumatic hyphema) and others ( 11 , 12 ) .

In recent years, the use of nanoparticles has been increasing rapidly and the development of various drugs is moving towards the nanomaterial system. Unique features of these compounds include their small size (1 - 100 nm), their reactivity, and their ability to change surface properties . Nano drugs can be administered in various forms such as topical, subcutaneous, oral, injectable and also inhaled . Excretion of these compounds, depending on the size, method of administration and their shape and other surface characteristics (such as electrical charge), can be done through the kidneys, liver and lungs ( 13 , 14 ) .

In this study, using nanotechnology, tranexamic acid nanoparticles were fabricated and its effect on reducing adhesion induced by laparotomy in rats was investigated ( grossly and histopathological ) .

## **Materials and methods**

This research was conducted at the Faculty of Specialized Veterinary Sciences, Science and Research Branch, Tehran, Iran, with the permission of the Ethics Committee of Islamic Azad University Science and Research Branch ( with letter No. 1400348 )

### **Surgical procedure**

In this study, 30 male Wistar rats , with an average age of 4 months and an average weight of 300 - 350 g , were used . Rats were randomly divided into 3 equal groups: the first group, the group treated with nano drug tranexamic acid ( 50 mg/kg ) , the second group, the group treated with tranexamic acid drug ( 50 mg/kg ) and the third group, the control group (treated with normal saline) . The rats were not fed the night before surgery, and then on the day of surgery, they were all anesthetized by intramuscular injection of ketamine 10 % (50 mg / kg) and xylazine 2% (5 mg / kg) ( 15 ) . The site for surgical incision in the midline of the abdomen was scrubbed with povidone – iodine 2.5 % and prepared for surgery . A 3 cm incision was made in the midline . After entering the peritoneal cavity , To induce standard adhesion, three 2 cm longitudinal incisions were made on the right side of the abdominal wall (inner surface) with surgical blade ( No.4 ) . To ensure intra-abdominal adhesion , some 2 × 2 cm pieces were removed from the inner surface of the abdominal

wall (left side ) with surgical scissors ( 15 ) . At the end, the abdominal incision was sutured with 3.0 absorbable monofilament vicryl sutures (with simple interrupt pattern at 1 cm intervals ) . The fascia and midline muscles were also sutured with 2.0-absorbent monofilament vicryl sutures . Finally, the skin was sutured using 3.0 non-absorbable monofilament Nylon sutures . The temperature of the operated rats was maintained by a heat lamp between 36-38 ° C .

### Treatments

30 male Wistar rats were randomly divided into three equal groups and primary surgery was performed on them . The duration of the treatment period is 28 days and the day of lesion formation is considered as the first day of the treatment period . In the first group, after induction of adhesion, nano-drug tranexamic acid ( 50 mg/kg ) was administered intraperitoneally . In the second group, tranexamic acid drug ( 50 mg/kg ) was administered intraperitoneally after induction of adhesion and In the third group, which was considered as the control group, after induction of adhesion, normal saline was used intraperitoneally .

### Macroscopic evaluation

On days 14 and 28 of the treatment period (after surgery), laparotomy was performed again and the adhesions were examined by the same surgeon and graded . According to Table 1, the degree of severity of each adhesion was evaluated separately and compared with each other ( 16 ) .

Table 1 : Score and macroscopic classification of abdominal adhesions in rats ( 16 ) .

Score	Description
0	No adhesive bands
1	One thin, non-vascular, easily removable
2	Two non-vascular, easily removable
3	Three non-vascular, easily removable
4	More than 3 non-vascular, easily removable

### Histopathological evaluation

On days 14 and 28 of the treatment period (after surgery), samples were taken from the adherent tissues and the samples were placed in 10% formalin solution for 2 days. Samples were cut to a diameter of 4 µm and stained using Harri's hematoxylin and alcoholic eosin technique to prepare for histopathological evaluation . The prepared slides were evaluated under a microscope with a magnification of 100 ( 15 , 17 ) . Adhesions were graded separately based on the severity of fibrosis and inflammation, according to Table 2 ( 15 ) .

Table 2 : Histopathological criteria for grading adhesions ( 15 )

Score	Degree of inflammation	Severity
0	No inflammation	no
1	Giant, lymphocytes, plasma cells	Mild

2	Giant, plasma cells, eosinophils	Moderate
3	Inflammatory cell infiltration	Severe

### **Data analysis**

In order to collect information, rats and samples were numbered and a checklist was designed for each of them separately to record information, including all types of variables under study ( such as the degree of macroscopic adhesion and histopathological factors ) .

Finally, the information obtained was analyzed by SPSS v.24 software and using the Kruskal-Wallis Test, and  $P < 0.05$  was considered statistically significant . In this method, qualitative data (such as intensity of adhesion, fibrosis and inflammation) are displayed quantitatively .

### **Results :**

#### **Macroscopic examination:**

by macroscopic examination on days 14 and 28, no sign of ascites or intra-abdominal fluid was observed in any of the groups, and during the treatment period, none of the rats, due to infection or Intestinal obstructions have not been destroyed . Macroscopic examination on the 14th day after surgery has shown that the lowest rate of intra-abdominal adhesion formation was related to the group treated with the nanodrug tranexamic acid (50 mg/kg). The highest rate of adhesion formation also occurred in the control group and in terms of intra-abdominal adhesion formation, there was a significant difference between the control group and the group treated with nanodrug tranexamic acid ( $P < 0.05$ ) .

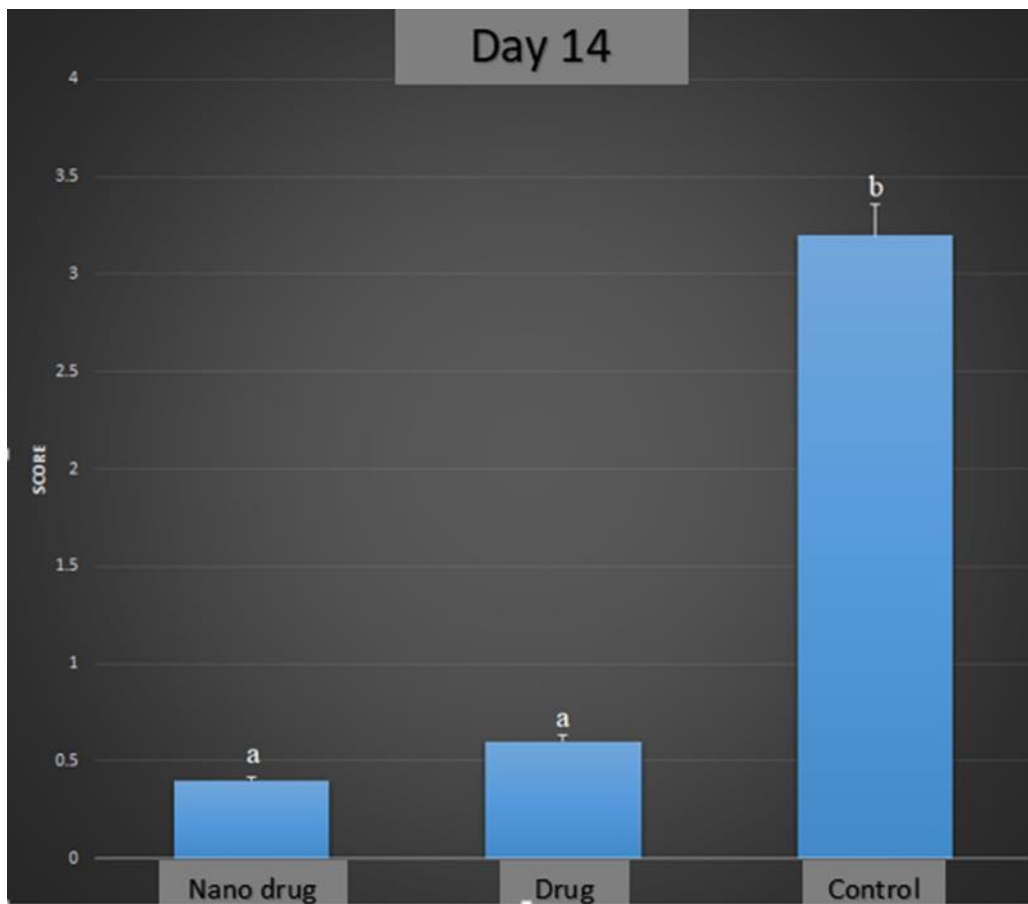


Figure 1 : Graph of macroscopic examination of adhesion in treatment and control groups on day 14.

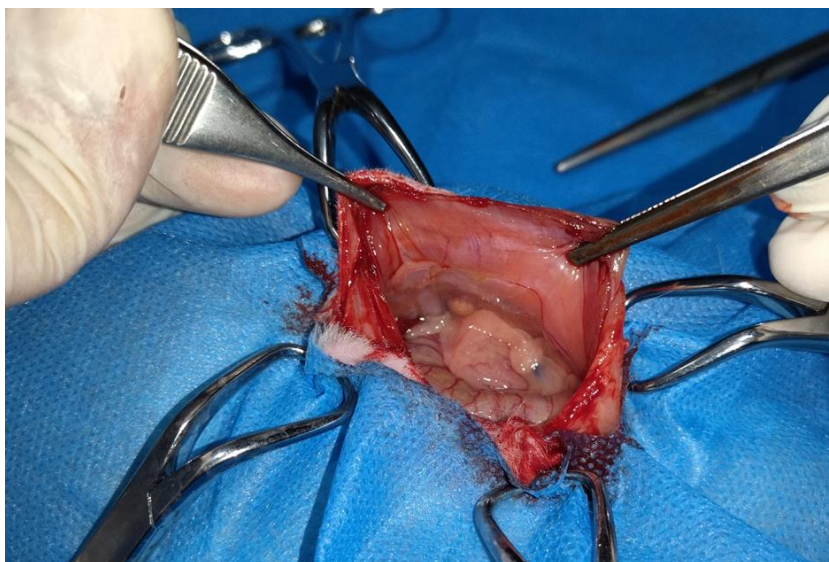


Figure 2 : Macroscopic image of Nano drug tranexamic acid (50 mg) group on day 14, with no adhesions.

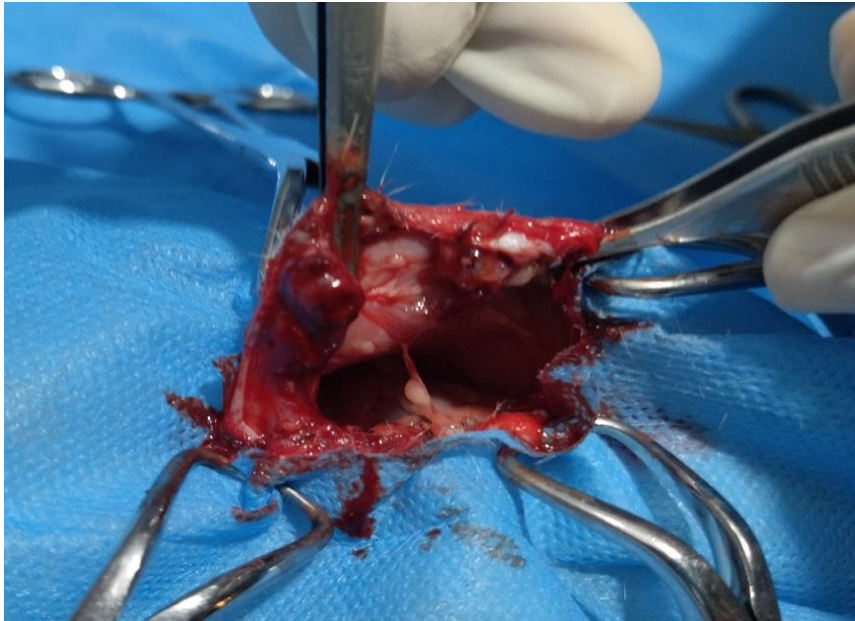


Figure 3 : Macroscopic image of tranexamic acid drug (50 mg) group on day 14, with low adhesion .

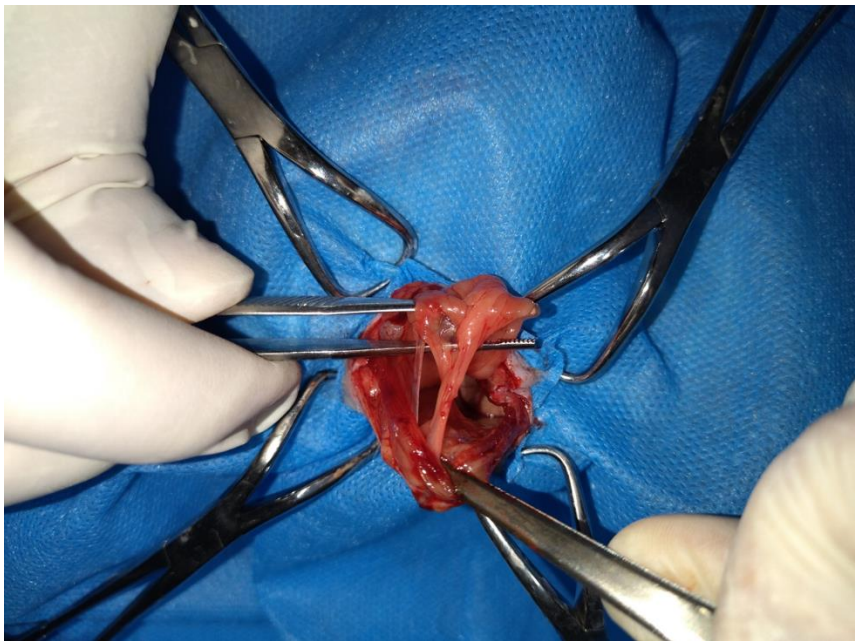


Figure 4 : Macroscopic image of control group on day 14, with severe adhesions.

Also, the macroscopic examination on the 28th day after the surgery has also shown that the lowest and highest amount of intra-abdominal adhesion formation was in the treatment group with nanodrug tranexamic acid (50 mg/kg) and the control group, respectively. There was a significant difference between these two groups ( $P < 0.05$ ) .



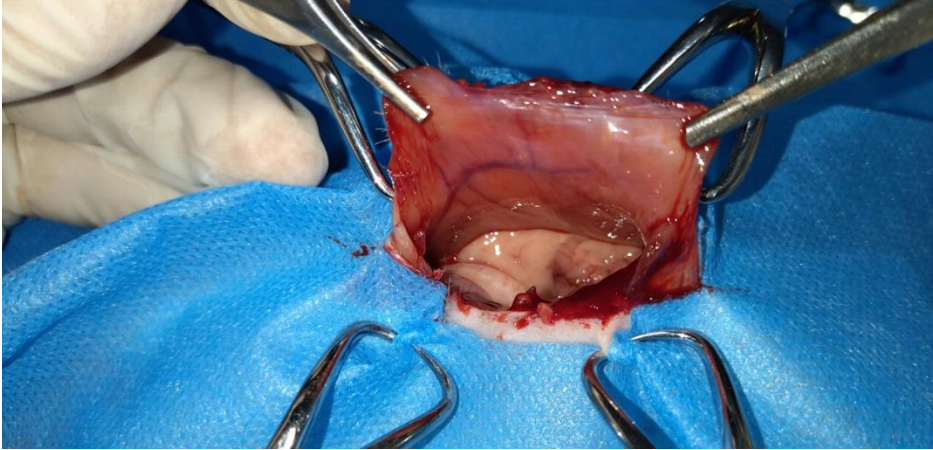


Figure 5 : Macroscopic image of Nano drug tranexamic acid (50 mg) group on day 28 , with no adhesions.

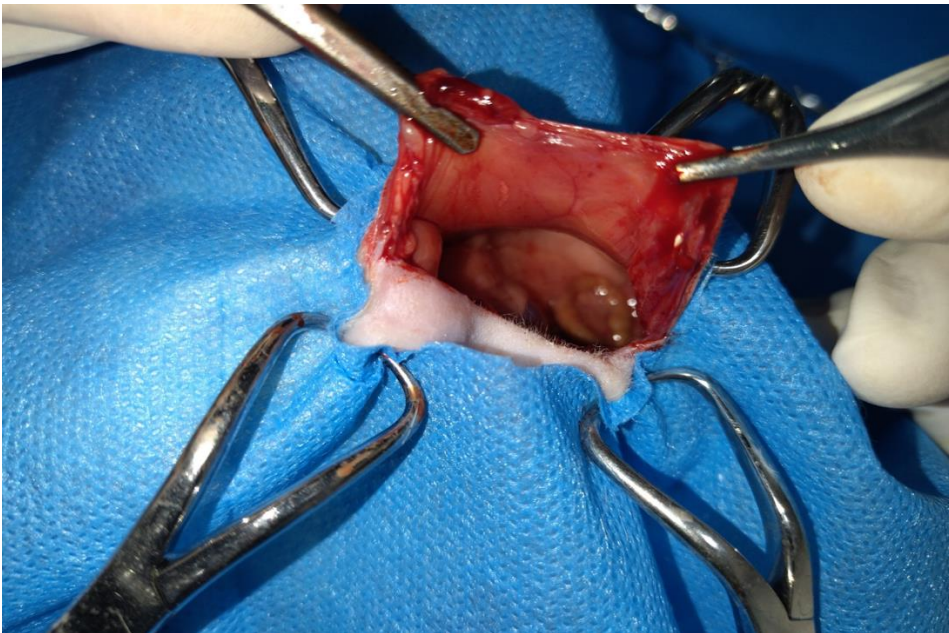

Figure 6 : Macroscopic image of tranexamic acid drug (50 mg) group on day 28 , with no adhesions.

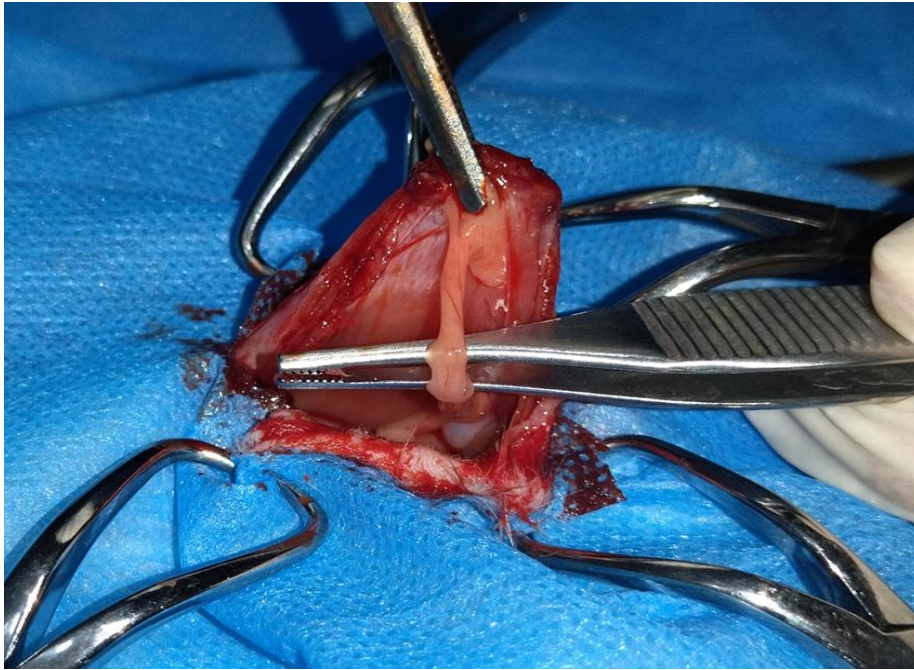


Figure 7 : Macroscopic image of control group on day 28 , with severe adhesions .

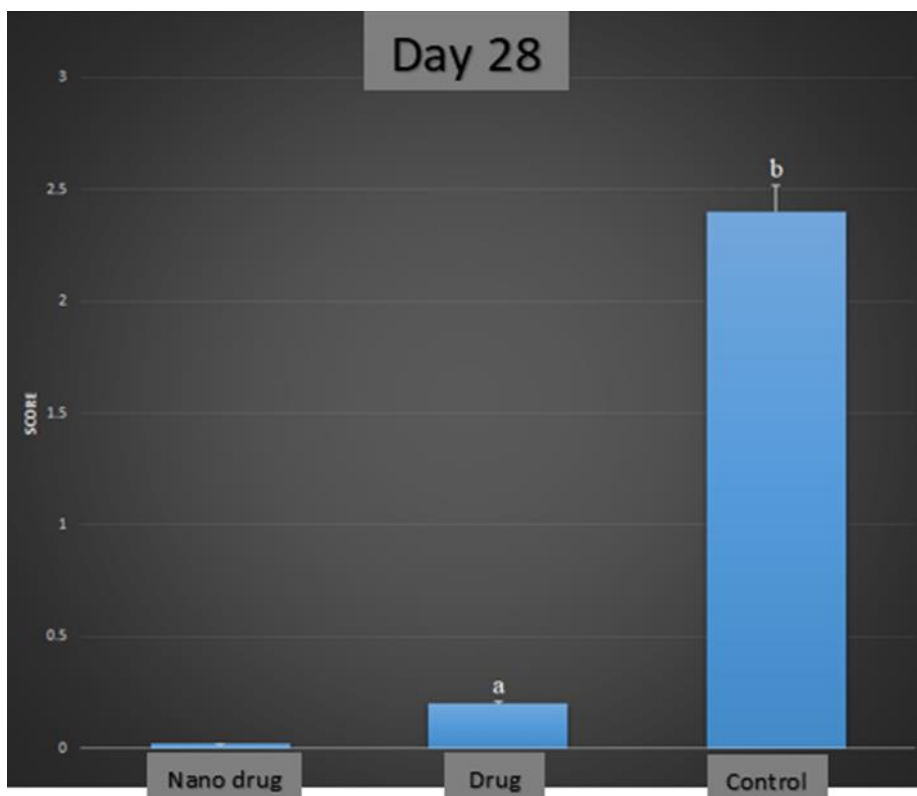


Figure 8 : Graph of macroscopic examination of adhesion in treatment and control groups on day 28.



### Microscopic examination :

The results of the evaluation of histopathological slides have shown that the lowest inflammation index on the 14th day after surgery was related to the group treated with the nanodrug tranexamic acid ( 50 mg/kg ) .Also, the control group has the highest inflammation index , and there was a significant difference between this group and the groups treated with nanodrug and tranexamic acid drug (  $P < 0.05$  ) . Microscopic examination of the fibrosis index, on the 14th day after surgery, has shown that the lowest level was related to the groups treated with the nanodrug tranexamic acid ( 50 mg/kg ) and tranexamic acid drug ( 50 mg/kg ) . Also, the highest level of fibrosis index was related to the control group, and there was a significant difference between this group and the groups treated with nanodrug and tranexamic acid drug (  $P < 0.05$  ) .

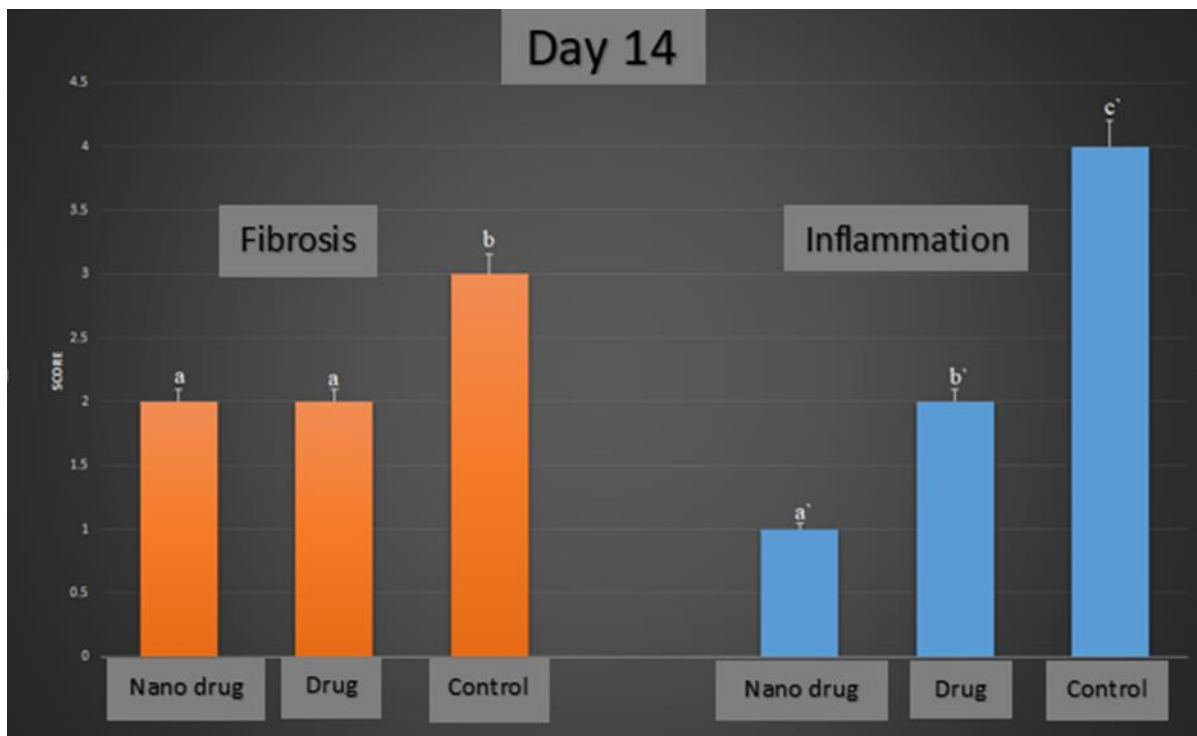


Figure 9 : Graph of microscopic examination of inflammation and fibrosis index in treatment and control groups on day 14 .

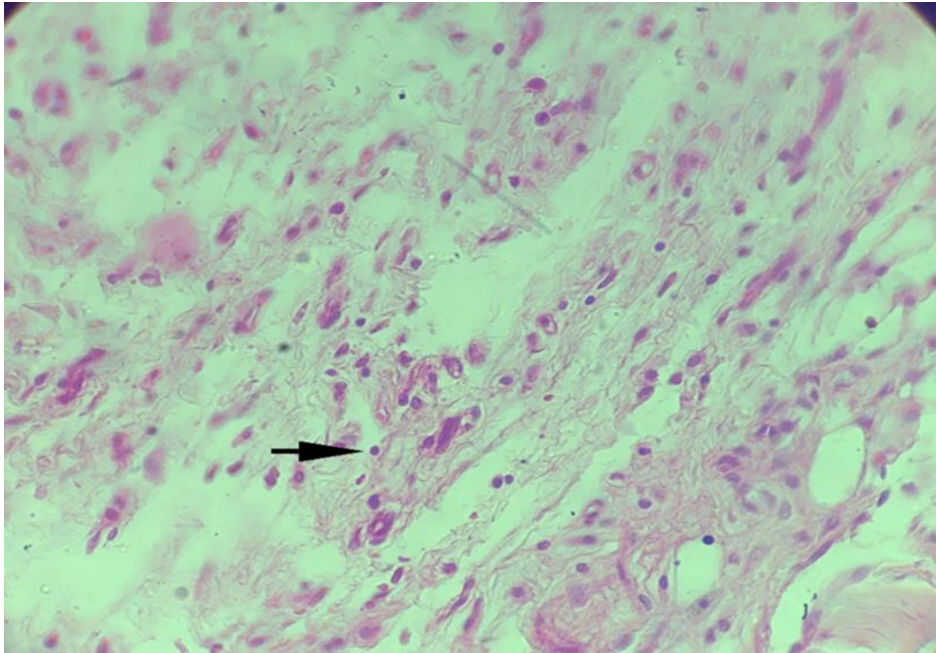


Figure 10 : Microscopic section from the abdominal wall, on day 14 post-operation, in the Nano drug tranexamic acid group , shows mild inflammation (H&E, 40X) .

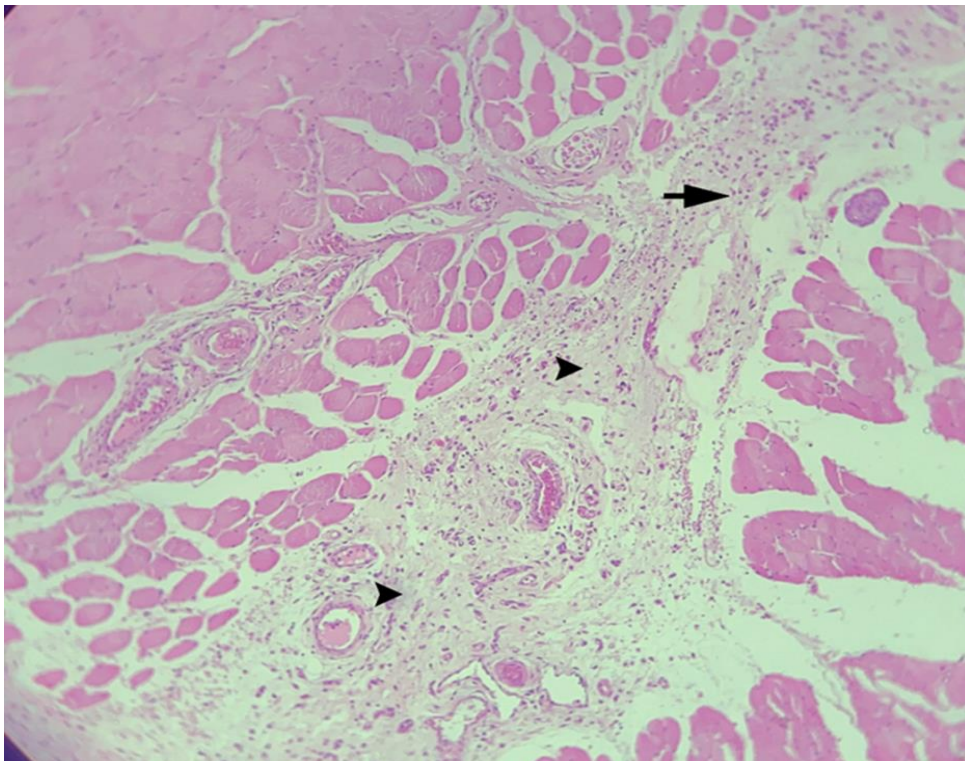


Figure 11 : Microscopic section from the abdominal wall, on day 14 post-operation, in the Nano drug tranexamic acid group , shows Low penetration of fibrotic tissue ( arrowhead ) and mild inflammation ( arrow ) (H&E, 10X) .

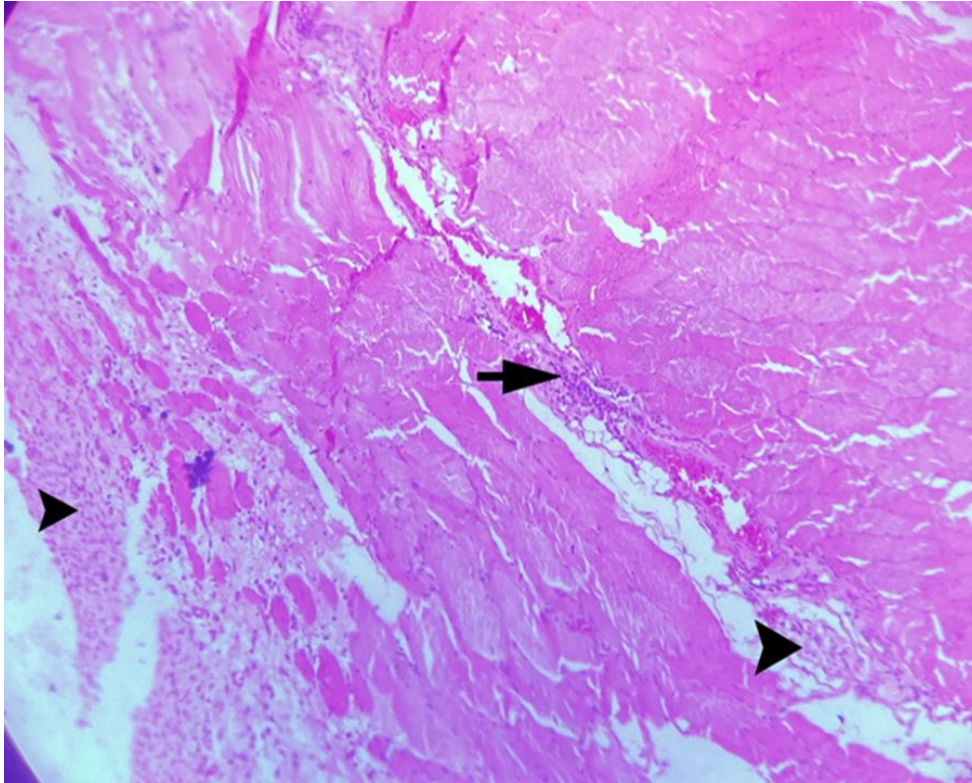


Figure 12 : Microscopic section from the abdominal wall, on day 14 post-operation, in the tranexamic acid drug group , shows Moderate infiltration of fibrotic tissue ( arrowhead ) and low inflammation ( arrow ) (H&E, 10X) .



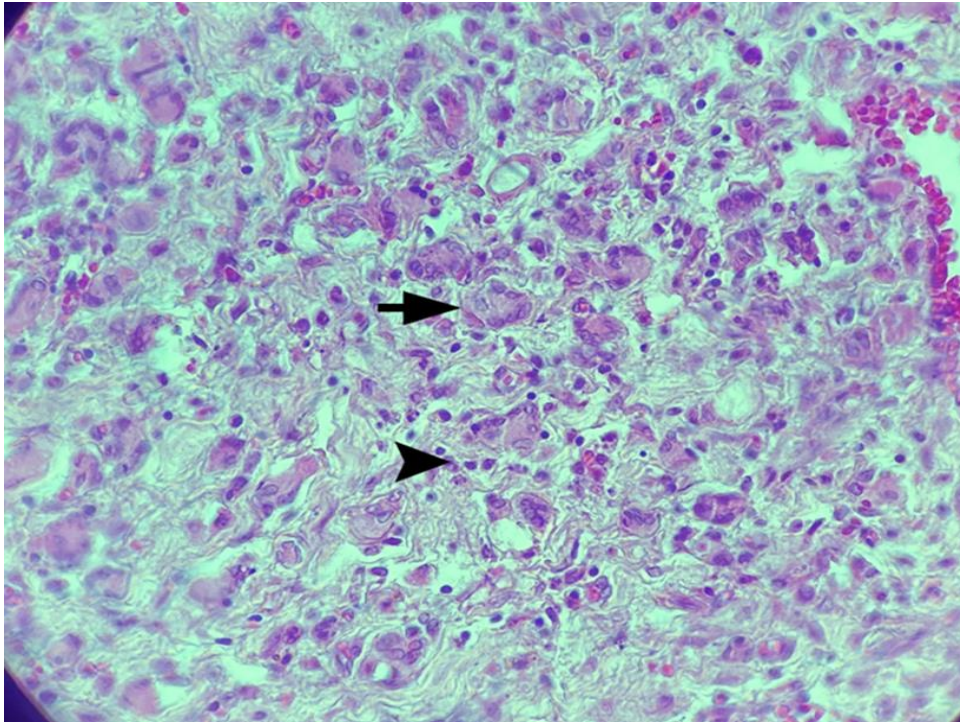


Figure 13 : Microscopic section from the abdominal wall, on day 14 post-operation, in the Control group , shows Severe inflammation ( arrowhead ) and infiltration of macrophages ( arrow ) (H&E, 40X) .

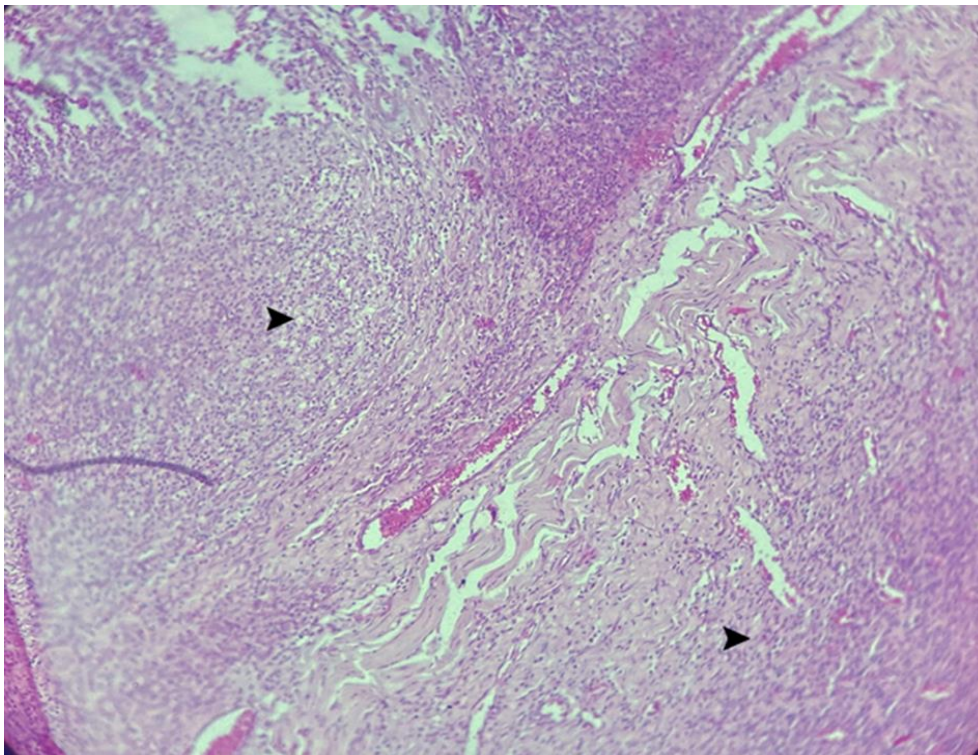


Figure 14 : Microscopic section from the abdominal wall, on day 14 post-operation, in the Control group , shows Severe infiltration of fibrotic connective tissue ( arrowhead ) (H&E, 10X) .

The histopathological examination on the 28th day also showed the same results as the results obtained on the 14th day, so that the lowest level of inflammation and fibrosis index was related to the groups treated with the nano drug and the tranexamic acid drug ( 50 mg/kg ) , and the highest amount of inflammation and fibrosis was observed in the control group, and also a significant difference was observed between the control group and the two treatment groups .

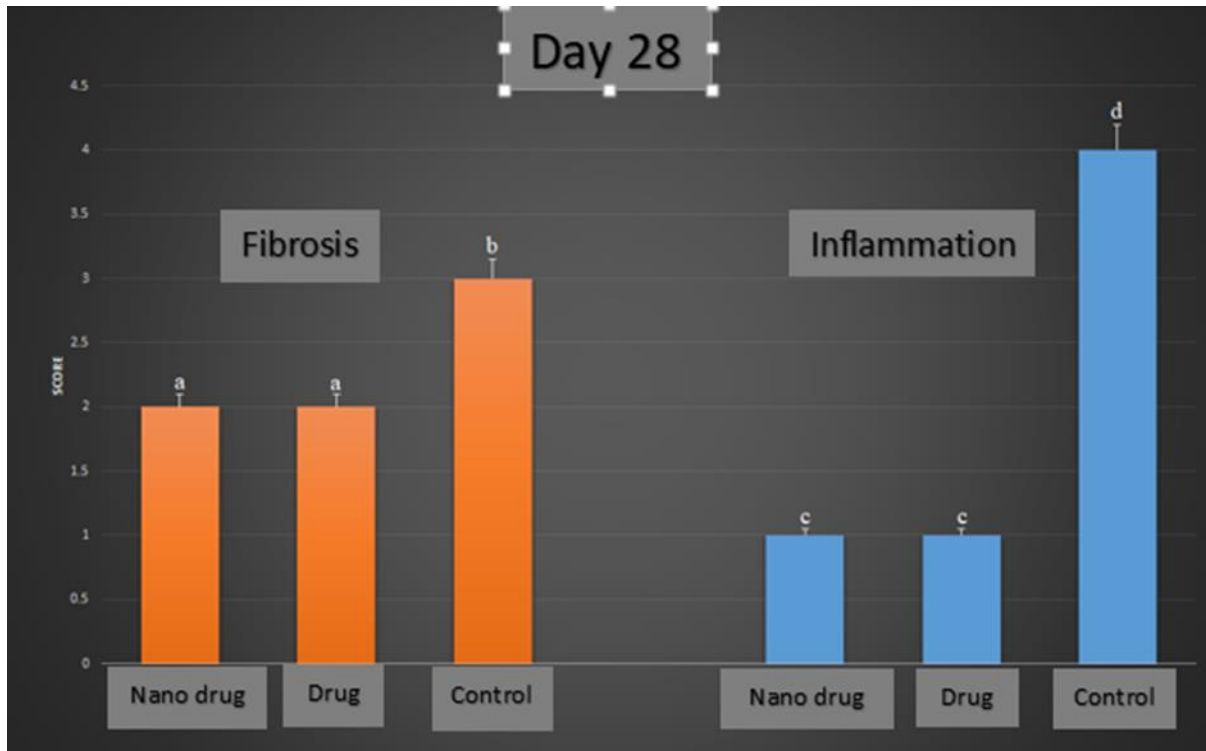


Figure 15 : Graph of microscopic examination of inflammation and fibrosis index in treatment and control groups on day 28 .



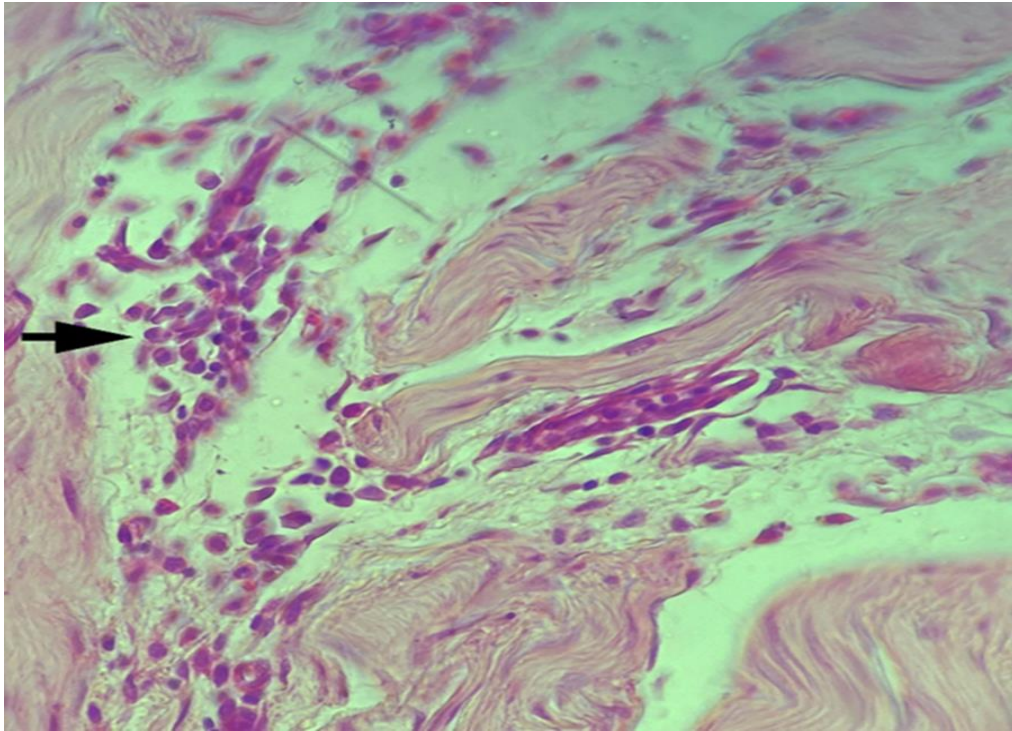


Figure 16 : Microscopic section from the abdominal wall, on day 28 post-operation, in the Nano drug tranexamic acid group , shows mild inflammation ( arrow ) (H&E, 40X) .

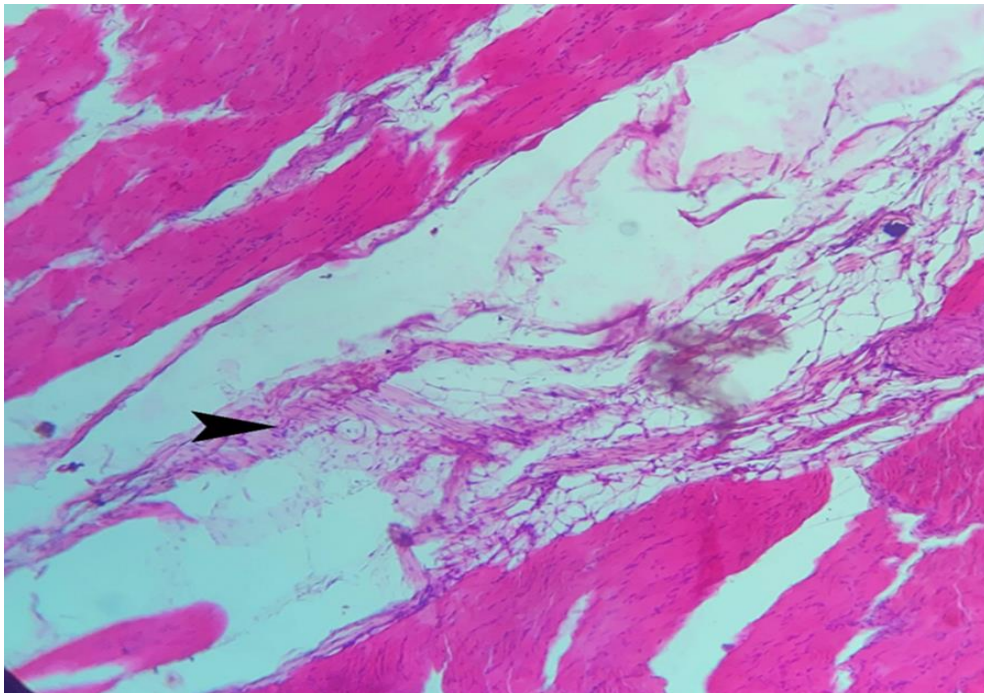


Figure 17 : Microscopic section from the abdominal wall, on day 28 post-operation, in the Nano drug tranexamic acid group , shows mild fibrotic tissue formation (H&E, 10X) .

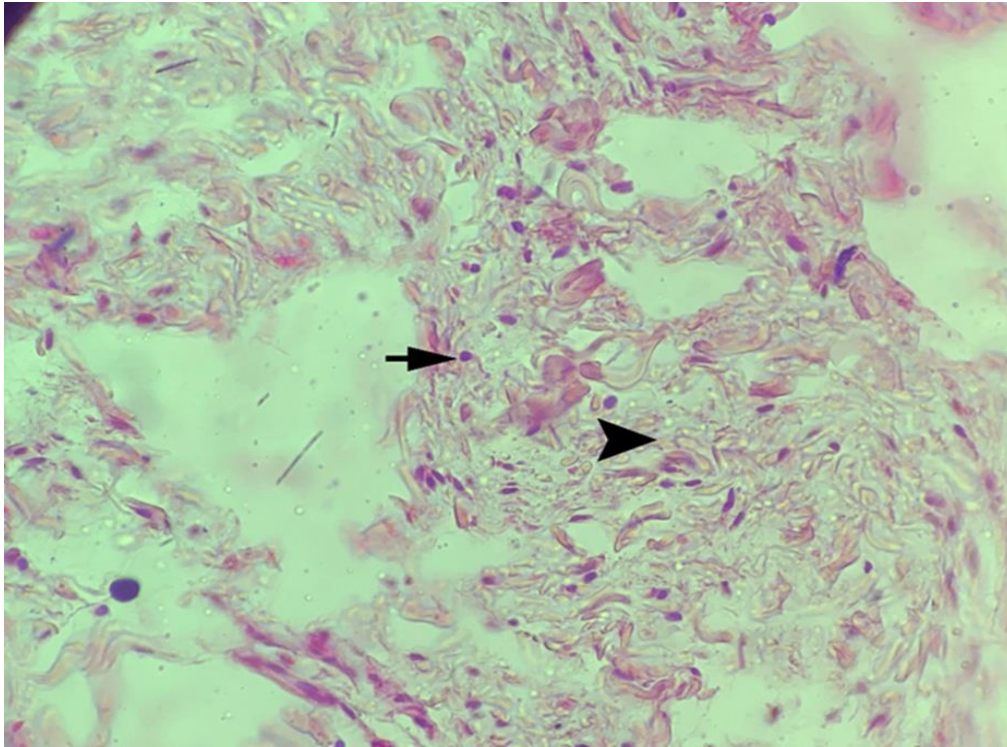


Figure 18 : Microscopic section from the abdominal wall, on day 28 post-operation, in the tranexamic acid drug group , shows low inflammation ( arrow ) and moderate fibrosis ( arrowhead ) (H&E, 40X) .

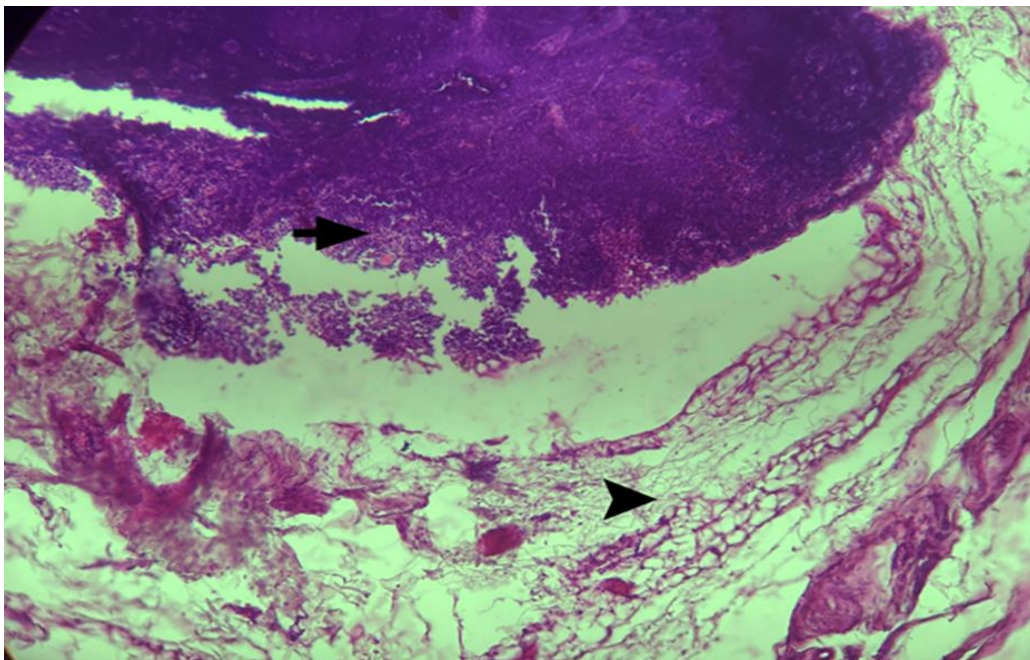


Figure 19 : Microscopic section from the abdominal wall, on day 28 post-operation, in the Control group , shows severe inflammation and microabscess ( arrow ) (H&E, 40X) .



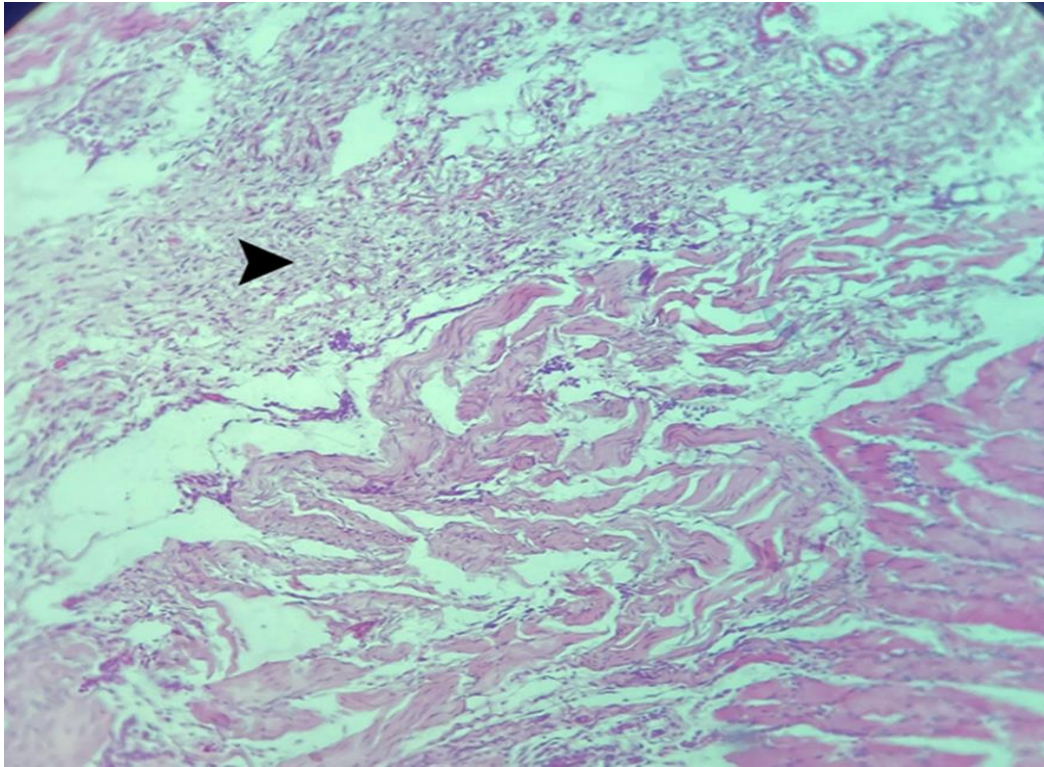


Figure 20 : Microscopic section from the abdominal wall, on day 28 post-operation, in the Control group , shows severe infiltration of fibrotic tissue ( arrowhead ) (H&E, 10X) .

#### Discussion :

The aim of this study was to investigate the effect of tranexamic acid nanoparticles on the reduction of adhesions caused by laparotomy . The macroscopic evaluation of the treatment groups has shown that the formation of adhesions in the group treated with the nanodrug tranexamic acid (50 mg/kg) was significantly less compared to the control group . Also, the histopathological examination of the slides prepared from adhesion lesions have also shown that the inflammatory response and the formation of fibrotic tissue in the group treated with the nanodrug tranexamic acid (50 mg/kg) have been significantly lower compared to the control group .

Intra-abdominal adhesions are among the complications that occur in more than 50% of abdominal surgery cases and lead to post-surgery problems . These lesions cause intra-abdominal organs to be connected to each other and cause complications such as obstruction of the small intestines, chronic pains in the abdominal area, and infertility (in females) . These adhesions can remain without clinical symptoms for a long time, and we are not able to detect them with the usual imaging and laboratory methods (1 , 2) .

During a study, it has been proven that in 95% of patients who have already undergone laparotomy surgery, adhesions can be detected in the abdominal cavity . In that study, the causes of laparotomy are gastrointestinal surgery, hysterectomy, ectopic pregnancy, as well as liver and gall bladder surgery (3) .

During the last decade, several methods have been evaluated to reduce the amount of adhesions caused by abdominal surgery . The mentioned methods reduce the amount of adhesion through different mechanisms such as reducing the amount of bleeding in the area or breaking down the accumulated fibrin mass in the area . The compounds that have been used for this purpose include coagulants, fibrinolytic agents, anti-inflammatory drugs, antibiotics, and mechanical barriers . Since

the mentioned mechanical barriers cannot be easily used in the site of lesions, there is a need to make a combination that can be easily placed in the site of lesions through a laparoscopic approach (18) .

Tranexamic acid is a synthetic analog of the amino acid lysine, which can prevent the conversion of plasminogen to plasmin by blocking the binding site of lysine on plasminogen, thus exerting its antifibrinolytic effect . The antifibrinolytic property of tranexamic acid has made it possible to use it in cases where hemostasis is required . For example, this drug can be used in heart surgeries, orthopedic surgeries, liver surgeries, and traumatic injuries where there is a possibility of bleeding . The effectiveness and safety of using tranexamic acid intravenously, intra-articularly , orally, topically, or a combination of the aforementioned methods, has been proven by numerous articles (8 , 9) .

Making compounds with bleeding control properties is of great importance, because the use of such compounds in cases of severe bleeding can save the patient's life . Gelatin is one of the materials that has been used many times for this purpose. During a study, the effect of the combination of gelatin and tranexamic acid on reducing the amount of internal bleeding has been investigated . The result of this study has shown that the compound made is very effective in controlling internal bleeding, so its use in cases of internal bleeding is safe (19) .

Tranexamic acid administration generally reduces the amount of bleeding and the need for blood transfusion in patients. Despite this, there has always been a risk of intravascular thrombus formation, as well as stroke and heart attack, in the use of this drug . In relation to this issue, a study has been conducted in which the possibility of intravascular thrombus formation as well as cerebral and cardiac stroke following the administration of tranexamic acid has been investigated . In this study, a number of patients who underwent heart surgery were prescribed tranexamic acid . The results of this study show that patients receiving tranexamic acid, in addition to less bleeding and need for blood transfusion, have a lower chance of intravascular thrombus formation as well as stroke and heart attack ( 12 ) .

## **Conclusion**

According to the conducted study, the local administration of nano drug tranexamic acid with the dose of 50 mg/kg has significantly reduced intra-abdominal adhesions after laparotomy surgery . Also, the use of this compound has reduced the inflammatory response and the formation of fibrotic tissue in the place of adhesion induction .

## References :

- 1 . Jahandideh, Alireza, Gholamreza Abedi, and Abolfazl Akbarzadeh. "Histopathological assessment of nano n-acetyl cysteine effect on postoperative adhesion in rats." *Iraqi Journal of Veterinary Sciences* 35.3 (2021): 589-597.
- 2 . Tabibian, N., et al. (2017). "Abdominal adhesions: A practical review of an often overlooked entity." *Annals of Medicine and Surgery* 15: 9-13.
- 3 . Ellis, H., et al. (1999). "Adhesion-related hospital readmissions after abdominal and pelvic surgery: a retrospective cohort study." *The Lancet* 353(9163): 1476-1480.
- 4 . Tulandi, T. and A. Al-Shahrani (2005). "Adhesion prevention in gynecologic surgery." *Current Opinion in Obstetrics and Gynecology* 17(4): 395-398.
- 5 . Kössi, J., et al. (2004). "The epidemiology and treatment patterns of postoperative adhesion induced intestinal obstruction in Varsinais-Suomi Hospital District." *Scandinavian journal of surgery* 93(1): 68-72.
- 6 . Fortin, C. N., et al. (2015). "Predisposing factors to post-operative adhesion development." *Human reproduction update* 21(4): 536-551.
- 7 . Iwasaki, K., et al. (2019). "Pharmacological mobilization and recruitment of stem cells in rats stops abdominal adhesions after laparotomy." *Scientific reports* 9(1): 1-8.
- 8 . Wang, D., et al. (2018). "The antifibrinolytic and anti-inflammatory effects of multiple doses of oral tranexamic acid in total knee arthroplasty patients: a randomized controlled trial." *Journal of Thrombosis and Haemostasis* 16(12): 2442-2453.
- 9 . Ng, W. C. K., et al. (2015). "Tranexamic acid: a clinical review." *Anaesthesiology intensive therapy* 47(4): 339-350.
- 10 . Ker, K., et al. (2012). "Effect of tranexamic acid on surgical bleeding: systematic review and cumulative meta-analysis." *Bmj* 344.
- 11 . Brenner, A., et al. (2018). "The impact of early outcome events on the effect of tranexamic acid in post-partum haemorrhage: an exploratory subgroup analysis of the WOMAN trial." *BMC pregnancy and childbirth* 18(1): 1-9.
- 12 . Smith, J. A., et al. (2017). "Tranexamic Acid in Patients Undergoing Coronary-Artery Surgery."
- 13 . Bose, T., et al. (2014). "Overview of nano-drugs characteristics for clinical application: the journey from the entry to the exit point." *Journal of nanoparticle research* 16(8): 1-25.
- 14 . Nikolić, V., et al. (2019). Administration routes for nano drugs and characterization of nano drug loading. *Characterization and biology of nanomaterials for drug delivery*, Elsevier: 587-625.
- 15 . Parsaei, P., et al. (2013). "Bioactive components and preventive effect of green tea (*Camellia sinensis*) extract on post-laparotomy intra-abdominal adhesion in rats." *International Journal of Surgery* 11(9): 811-815.



16 . Lorenz, E., et al. (1997). Pathophysiology and classification of adhesions. Peritoneal adhesions, Springer: 29-34.

17 . Atarbashe, R. K. and A. Abu-Raghif (2020). "Comparative treatment of induced ulcerative colitis in male rat model by using cinnarizine and sulfasalazine." Iraqi Journal of Veterinary Sciences 34(2): 465-472.

18 . Diamond, M. P., et al. (2011). "A prospective, controlled, randomized, multicenter, exploratory pilot study evaluating the safety and potential trends in efficacy of Adhexil." Fertility and sterility 95(3): 1086-1090.

19 . Sezer, U. A., et al. (2016). "Combination of gelatin and tranexamic acid offers improved haemostasis and safe use on internal hemorrhage control." RSC advances 6(97): 95189-95198.

